

**Surface Anatomy**  
**Notes from Mr Tulloh's Seminar**

**HEAD:**

-Middle Meningeal Artery- extradural haematoma

-Sup Temporal Artery- biopsy site

NB- parallel incision so not to cut Facial or Trigeminal nerve

Branches Facial:

Tall- Temporal

Zulus- Zygomatic

Bear- Buccal

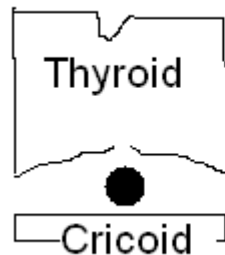Many- Mandibular

Children- Cervical

# cheek- injury to infra-orbital nerve- numb upper lip

**NECK:**

- Tracheotomy- cricothyroid membrane



Supine: 1cm to work in

- VT- Carotid Sinus Massage
  - o Bifurcates at hyoid bone (level with mandible)
- IJVein- between two heads of sternomastoid muscle
  - o Emergency central line
  - o Anaesthetist would put it higher
- Accessory Nerve- in post triangle of neck. Runs between sternomastoid and Trapezius

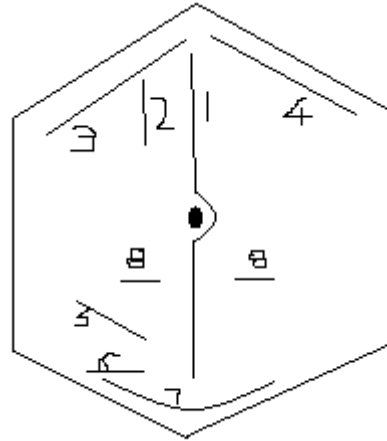
**CHEST:**

- Pleura- Mid axial line. T8- round about level of bottom of lung
  - Lower than this, likely to hit liver with biopsy
  - o Up to nipple at highest level (peak of expiration)
  - o Chest drain- 5<sup>th</sup> intercostal space (unlikely to hit liver)

**ABDO:**

- Aortic Aneurysm- feel above umbilicus (bifurcates at umbilicus)
- Trans-pyloric plane: pylorus, pancreas, splenic artery, gallbladder, transverse colon
- Scars:

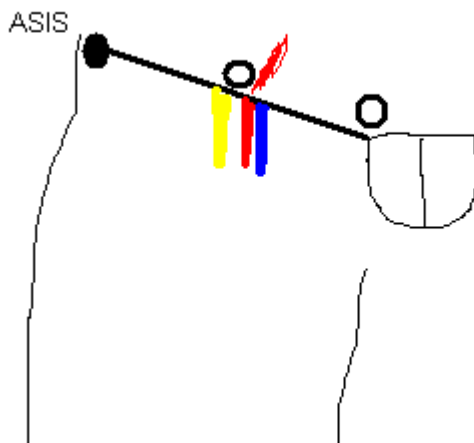
1. Midline
2. Paramedian
3. Kocher's (Right Subcostal)
4. Left Subcostal
5. Gridiron (through McBurney's)
6. Lanz
7. Pfannensteil
8. Closure Colostomy



NB- incisional hernia

And specifically, pfannensteil hernia would be in superior midline (smile is only skin incision)

Inguinal Hernias:



NAV- Yfronts

Fem art- mid inguinal point

Deep Ring- mid point of inguinal ligament (from pubic tubercle)

Origin indirect hernia (common younger men), which would also go over inf. Epigastric artery

Medial to fem vein- fem canal- Cloquet's node overlies it (lump could be lipoma)

To feel pubic tubercle, feel up adductor longus

Fem hernia- below tubercle

Inguinal hernia- above tubercle

Woman- round ligament at deep ring

Male- Vas deferens and vessels

Both- Genito-femoral nerve to scrotum/labia

Tunnel- Floor- inguinal ligament

Roof is Conjoint Tendon

*(written up by James Blackmur, ESSS Publicity Secretary 2008/09)*